



PATIENT

Monte Sprengel

SPECIES

Canine

BREED

Dalmatian

SEX

Male Neutered

AGE

13 years

WEIGHT

82.2lbs

PRESENTING CLINICAL SIGNS

History: Grade III/VI heart murmur; no clinical signs. BP: 133, 135, 135mmHg.

ECHOCARDIOGRAM FINDINGS

2D, m-mode, color flow and Doppler imaging is available.

Left ventricle: The LV diameter is normal with adequate myocardial function. LV wall thicknesses are normal.

Left atrium: The left atrium is normal.

Mitral valve: The mitral valve is mildly thickened with no prolapse into the left atrial lumen. Mild eccentric mitral regurgitation with a normal velocity.

Aortic valve/aorta: The aortic valve is mildly thickened. Normal aortic outflow velocity; laminar flow. Mild aortic insufficiency.

Right ventricle: Normal right ventricular diameter and morphology indicating no overt evidence of pulmonary arterial hypertension.

Right atrium: Normal RA dimension.

Tricuspid valve: The tricuspid valve appears mildly thickened with mild tricuspid regurgitation; normal velocity.

Pulmonic valve/pulmonary artery: The pulmonic valve is normal in morphology and mobility. No pulmonic insufficiency. Normal RVOT velocity; laminar flow.

Pericardium/other: No pericardial or pleural effusion noted. No obvious cardiac masses.

Heart rhythm: ECG reveals a sinus rhythm with an average HR of 120bpm.

2-Dimensional Measurements

Ao diam (cm)	2.9
LA diam (cm)	3.2
LA:Ao (Swe)	1.1
IVS thickness (cm)	1.1
LVID diastole (cm)	4.5
PW thickness (cm)	1.1
LVID systole (cm)	2.8
FS (%)	39

Doppler Measurements

PV Vmax (m/s)	0.8
AoV Vmax (m/s)	1.5
MR Vmax (m/s)	5.6
TR Vmax (m/s)	2.5
TR PG (mmHg)	25

INTERPRETED BY

Maggie Machen
Lamy, DVM
DACVIM (Cardiology)

IMAGING PERFORMED BY

Pamela Harrigan,
RDCS

HOSPITAL NAME

Rhode Island Animal
Medical Center

REFERRING VET

Dr. Rogoff

INVOICE

21782

DATE

10/30/21

INTERPRETATION OF THE FINDINGS

The cause of the murmur is chronic degenerative valve disease causing mild mitral and mild tricuspid regurgitation. Lack of significant left atrial enlargement indicates the current risk for complication is low. A small aortic leak is noted; however, the reported blood pressure is normal. No additional issues are noted in this study. Assessment of progression in the future will help predict long term prognosis, which is highly variable at this stage (B1).

RECOMMENDATIONS

- In an asymptomatic dog without significant left atrial enlargement, no cardiac medications are clearly indicated.
- Omega fatty acid supplementation and mild salt restriction may be of some long-term benefit.
- No cardiac contraindication for general anesthesia prior to chamber enlargement.
- Monitor for development of a cough, labored breathing, exercise intolerance or collapse episodes.



PATIENT

Monte Sprengel

SPECIES

Canine

BREED

Dalmatian

SEX

Male Neutered

AGE

13 years

WEIGHT

82.2lbs

INTERPRETED BY

Maggie Machen
 Lamy, DVM
 DACVIM (Cardiology)

IMAGING PERFORMED BY

Pamela Harrigan,
 RDCS

HOSPITAL NAME

Rhode Island Animal
 Medical Center

REFERRING VET

Dr. Rogoff

INVOICE

21782

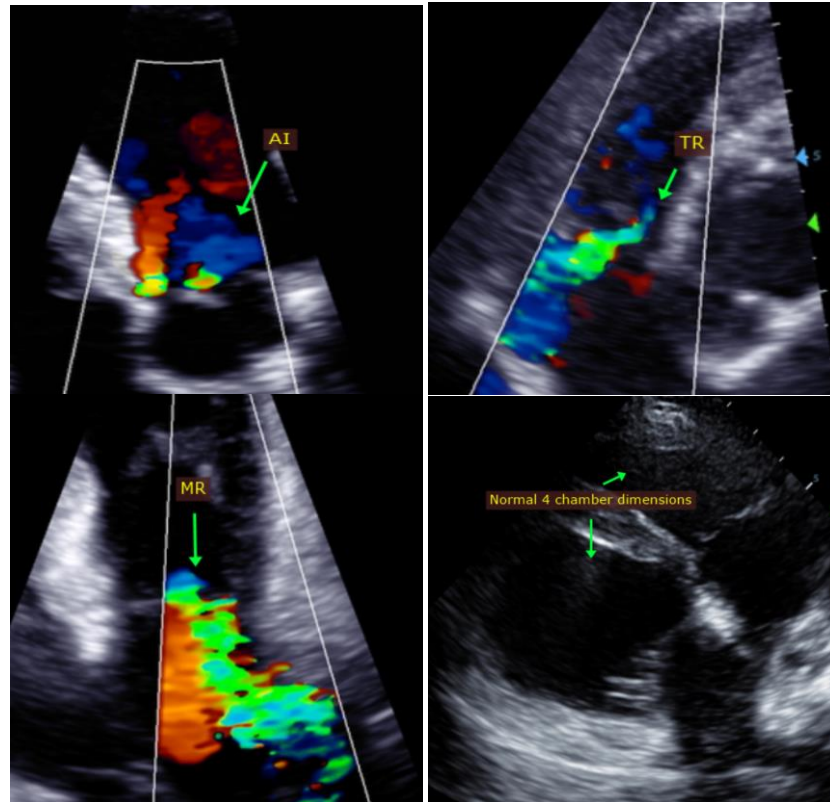
DATE

10/30/21

PLAN

- Recommend conservative monitoring with a recheck echocardiogram in 6-12 months, sooner if any development of clinical signs.

IMAGES



The information and recommendations provided are based on the images presented by the referring veterinarian. No evaluation can be communicated regarding pathology that was not visible in the image/video clips provided.

Thank you for this referral. This report was generated using transcription software, and minor dictation errors may be present. If the clinical or image interpretation does not parallel your findings or if I can be of any further assistance, please contact me.

Maggie Machen Lamy, DVM
 Diplomate of the American College of Veterinary Internal Medicine (Cardiology)
 info@sonopath.com